

April 2022

## A Novel Endo GIA™ Staple Cartridge for Canine Lung Lobectomies

Alissa St. Blanc

*Louisiana State University and Agricultural and Mechanical College*

Follow this and additional works at: [https://repository.lsu.edu/gradschool\\_theses](https://repository.lsu.edu/gradschool_theses)



Part of the [Small or Companion Animal Medicine Commons](#)

---

### Recommended Citation

St. Blanc, Alissa, "A Novel Endo GIA™ Staple Cartridge for Canine Lung Lobectomies" (2022). *LSU Master's Theses*. 5509.

[https://repository.lsu.edu/gradschool\\_theses/5509](https://repository.lsu.edu/gradschool_theses/5509)

This Thesis is brought to you for free and open access by the Graduate School at LSU Scholarly Repository. It has been accepted for inclusion in LSU Master's Theses by an authorized graduate school editor of LSU Scholarly Repository. For more information, please contact [gradetd@lsu.edu](mailto:gradetd@lsu.edu).

# **A NOVEL ENDO GIA™ STAPLE CARTRIDGE FOR CANINE LUNG LOBECTOMIES**

A Thesis

Submitted to the Graduate Faculty of the  
Louisiana State University and  
Agricultural and Mechanical College  
in partial fulfillment of the  
requirements for the degree of  
Master of Science

in

The Department of Veterinary Clinical Sciences

by

Alissa St. Blanc

B.S., Louisiana State University, 2013

DVM, Louisiana State University School of Veterinary Medicine, 2016

May 2022

## ACKNOWLEDGMENTS

I would like to thank my faculty, without whom this project would not have been possible. I am grateful to Dr. Rebecca Csomos, who readily accepted me as a mentee and helped me navigate the uncharted waters of a combined small animal surgery residency and Master of Science program at LSU. Your support and guidance throughout this program and throughout my residency were unparalleled. Thank you to Drs. Karanvir S. Aulakh, R. Avery Bennett, Jude Bordelon, Alberto Gines, and Chuck Walls who have likewise supported my research and residency endeavors. I am forever thankful for your support professionally and personally. Thank you to Dr. Mark Mitchell for his unending sense of humor and dedication to statistical methods. Thank you to Dr. Samithamby Jeyaseelan for his expertise and contributions as my graduate committee member.

Completion of my residency and Master of Science program was also made possible by our surgery team; those who are too often underappreciated. To my wonderful surgery technicians and my resident mates who made each day so much more fulfilling just by showing up to work, you are forever in my heart. Torri Collins-Cannon, Dr. David Cradic, Andi Laborde, Dr. Daniel McCarthy, Dr. Aki Otomo, Julia Perkins, Alice Price, Whitney Soma, and Dr. Jessica Sullivan, you are incredible people who I am so lucky to call friends.

I could never have survived the last three years without the support, comic relief, and inspiration from my family. You have been on-call babysitters, phone call therapists, and more. I would like to thank my husband Michael for his constant love and encouragement. You have been there for every failure and success. There is no way I

could detail every sacrifice you have made for our family, so I will simply say, “Thank you,” for making me a better wife, mother, and human every day.

# TABLE OF CONTENTS

ACKNOWLEDGEMENTS.....	ii
ABSTRACT.....	v
CHAPTER 1. INTRODUCTION.....	1
1.1. Canine Respiratory Anatomy.....	1
1.2. Canine Pulmonary Physiology.....	2
1.3. Canine Surgical Pulmonary Disease.....	8
1.4. Canine Lung Surgery.....	19
1.5. Summary.....	31
CHAPTER 2. INVESTIGATION AND VALIDATION OF A NOVEL ENDOSOPIC GASTROINTESTINAL ANASTOMOSIS (ENDO GIA™) STAPLE CARTRIDGE FOR CANINE LUNG LOBECTOMIES.....	33
2.1. Introduction.....	33
2.2. Objectives and Hypothesis.....	34
2.3. Materials and Methods.....	34
2.4. Results.....	40
CHAPTER 3. FINAL DISCUSSION AND CONCLUSIONS.....	42
3.1. Discussion.....	42
CHAPTER 4. FUTURE DIRECTIONS.....	46
4.1. Future Directions.....	46
APPENDIX. COPYRIGHT INFORMATION.....	48
REFERENCES.....	49
VITA.....	53

## ABSTRACT

The canine lungs are well suited for ventilation, gas exchange, and gas transport. In diseased states, changes within bronchi and pulmonary parenchyma alter the blood-gas interface. Diagnostic workups to characterize pulmonary disease may include blood gas analysis, bronchoalveolar lavage, tracheobronchoscopy, radiography and/or computed tomography. Surgical pulmonary diseases include cysts, bullae, and blebs; congenital anomalies; consolidation or abscessation; bronchiectasis; lacerations; lung lobe torsions; and neoplasia. Surgical options may include laceration repair, partial or total lung lobectomy, and pneumonectomy. These options are most commonly utilized in cases that fail medical management. Lung lobectomies were originally performed using suture ligation. Stapling devices have been commonly used since the 1980's.

The objectives of this study were to validate the 2.0 mm endoscopic gastrointestinal anastomosis (Endo GIA™) staple cartridge for lung lobectomies and to compare procedure time and air leakage incidence with that of suture ligation. Sixteen canine cadavers, 18-27 kilograms, were randomly assigned to total lung lobectomy of the right middle lung lobe through intercostal thoracotomy by suture ligation or the 2.0 mm Endo GIA™ staple cartridge. Procedure time was recorded. Following the lobectomy, the thoracic cavity was filled with water. Positive pressure was held at 20 cm H<sub>2</sub>O for 5 minutes. The bronchus was assessed for air leakage as evidenced by gas bubbles and the inability to maintain pressure at 20 cm H<sub>2</sub>O. Procedure time and air leakage incidence were compared between groups.

The 2.0 mm Endo GIA™ staple cartridge was successful for lung lobectomies in all cadavers. There was no significant difference ( $t=-0.856$ ,  $p=0.407$ ) in body weight

between groups. Procedure time was significantly shorter ( $p < 0.0001$ ) using the Endo GIA™ stapler compared to suture ligation. There was no significant correlation ( $r = 0.044$ ,  $p = 0.873$ ) between body weight and procedure time. There were no incidents of air leakage in either group. The 2.0 mm Endo GIA™ staple cartridge may be used for lung lobectomies in medium to large breed canine cadavers. The small staples deployed by this cartridge may provide more complete compression of hilar vessels and bronchi, theoretically resulting in reduced hemorrhage and air leakage, and reduced thoracic contamination in patients with infection or neoplasia.

# CHAPTER 1. INTRODUCTION

## 1.1. Canine Respiratory Anatomy

The canine respiratory tract can be divided into two zones: the conducting zone and the respiratory zone. The conducting zone includes the nares, pharynx, larynx, trachea, bronchi, and most of the bronchioles. The major functions of this zone are to provide passageways for air to travel into and out of the lungs, remove debris and pathogens from this air, and thermoregulation both of the respiratory tract and the whole body. The trachea is a somewhat rigid tube consisting of 35-45 C-shaped cartilage rings traveling from the larynx toward the lungs. The C-shape is completed with a dorsal tracheal membrane composed of mucosa, connective tissue, and tracheal muscle. The rings alternate with an elastic annular ligament. At approximately the level of the fourth or fifth thoracic vertebra, the trachea divides into two principle mainstem bronchi. Bronchial walls consist of rings composed of hyaline cartilage and spiral bands of smooth muscle. These further divide into lobar bronchi, which supply each lung lobe and continue the dichotomous branching pattern. This branching pattern continues through segmental bronchi which supply each bronchopulmonary segment, subsegmental bronchi, terminal bronchioles, and respiratory bronchioles. Bronchioles decrease in diameter to less than 1 mm and contain no cartilage. Terminal bronchioles are the smallest airway without alveoli and therefore conclude the conducting zone of the respiratory tract, which is equivalent to anatomic dead space without the ability to conduct gas exchange. The respiratory bronchioles continue to divide into alveolar ducts, alveolar sacs, and pulmonary alveoli, which constitute the respiratory zone of the respiratory tract. This zone is responsible for the exchange of gas across the alveolar



blood-gas interface.

Normal canine lungs divide at the level of the lobar bronchi into six distinct lobes. The left lung is composed of a cranial and caudal lobe. The cranial lobe has cranial and caudal subsegments with a common lobar bronchus. The right lung is composed of cranial, middle, caudal, and accessory lobes.

Blood supply of the lungs includes pulmonary arteries, bronchial arteries, and pulmonary veins. Pulmonary arteries follow lobar distribution, coursing along the craniodorsal aspect of each bronchus. Bronchial arteries, branches of the bronchoesophageal arteries, supply airways to the level of the respiratory bronchioles. At this point, they become continuous with the pulmonary arteries within capillary beds. Pulmonary veins collect blood returning from pulmonary and bronchial arteries. Pulmonary veins course along the caudoventral aspect of the associated bronchus.

## **1.2. Canine Pulmonary Physiology**

The process of moving air in and out of the alveoli is called ventilation. The pleural space between the lungs and the thoracic wall has an existing negative pressure, which allows coupling between the lungs and the thoracic wall necessary for movement of air. The diaphragm is primarily responsible for inspiration during normal resting ventilation. This is accomplished when the diaphragm contracts, as it pulls the caudal lung surface caudally. Expiration is primarily accomplished by elastic recoil.<sup>1</sup> During activities such as exercise, the ventilatory demand is higher. The diaphragm is aided during inspiration by the actions of the external intercostal, sternocleidomastoid, scalenus, and ventral serratus muscles, which pull the ribs cranially and expand the

lungs outward. With increased ventilatory demand, expiration is aided by the contraction of the internal intercostal and abdominal rectus muscles.<sup>2</sup>

Within the alveoli, a pressure gradient exists that allows more efficient air movement.<sup>2</sup> At the beginning of inspiration, the alveolar pressure is below atmospheric pressure and air moves into the alveoli. Airflow stops at the end of inspiration, at which time the alveolar pressure and atmospheric pressure are equal. Elastic recoil creates a positive alveolar pressure during expiration to move air out of the alveoli.

During inspiration, the ability to ventilate depends on the ability to overcome tissue elastance, surface tension within the alveoli, and airway resistance.<sup>3</sup> Tissue elastance refers to the degree to which the lungs can recoil, or return to their normal dimensions, following removal of the distending forces. Tissue compliance is the reciprocal of elastance and refers to the distensibility of the lung. Compliance is lowest at high and low lung volumes and can be altered with pulmonary fibrosis or edema. Alveolar surface tension describes the tendency of alveoli to collapse, a force generated at the air-liquid interface. Alveolar type II cells produce a substance called surfactant, which decreases surface tension in normal alveoli. By decreasing surface tension, surfactant decreases the amount of work needed to distend the lungs, increasing compliance. This also prevents atelectasis by allowing changes in surface tension with variations in alveolar size. Airway resistance generated by the tissues of the airway contributes to the increase in work required for ventilation. During inspiration, the nares are responsible for 79% of the resistance. The larynx contributes 6%, and small airways cause 15% of the resistance. During expiration, the nares contribute 74% of the

resistance. The larynx is responsible for 3%, and the small airways cause 23% of the resistance.<sup>2,4,5</sup>

The drive for ventilation is closely controlled to match the metabolic need. The pons and medulla in the brain contain the respiratory center responsible for generating breathing rhythm and regulating tidal volume.<sup>1,2,6</sup> Ventilation is then adjusted based on feedback from chemical and neural reflexes. Chemoreceptor reflexes are most important for control. Peripheral and central chemoreceptors can be stimulated by the arterial partial pressure of oxygen ( $\text{PaO}_2$ ), arterial partial pressure of carbon dioxide ( $\text{PaCO}_2$ ), and pH.  $\text{PaCO}_2$  is the major stimulus for ventilation under most conditions and is therefore precisely controlled. Central chemoreceptors are responsible for the majority of the stimulus for ventilation. Peripheral chemoreceptors are also involved and have a faster response. The response to chemoreceptors is amplified when the  $\text{PaO}_2$  is low.

Because carbon dioxide ( $\text{CO}_2$ ) can diffuse through the blood-brain barrier, it is able to cause stimulation of the chemoreceptors on the ventral surface of the medulla.  $\text{CO}_2$  dissociates into bicarbonate ( $\text{HCO}_3^-$ ) and hydrogen ions ( $\text{H}^+$ ) in the extracellular fluid, which stimulates the chemoreceptors in the medulla.  $\text{CO}_2$  can also stimulate peripheral chemoreceptors in the carotid aortic bodies, leading to a faster but smaller response compared to that from the medulla.

Changes in the  $\text{PaO}_2$  have less effect on ventilation under normal circumstances. However, if  $\text{PaO}_2$  decreases to less than 60 mmHg, ventilation will increase, a phenomenon known as hypoxic ventilatory drive. In cases where  $\text{CO}_2$  responsiveness

has been altered such as in patients with chronic lung disease, this becomes more important for maintaining normal ventilation.

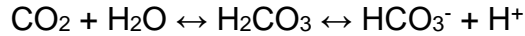All gases move across the alveolar blood-gas interface by passive diffusion. Fick's law states that the rate of transfer of a gas through a sheet of tissue is directly proportional to the surface area available for diffusion, the diffusion coefficient of the gas, and the difference in partial pressures between the two sides. It is also inversely proportionate to the thickness of the tissue.<sup>2</sup> At the alveolar wall, the lungs have an approximate surface area of 50-100 m<sup>2</sup> and thickness as small as 0.3 µm. These measurements are ideal for diffusion.<sup>2,6</sup> CO<sub>2</sub> diffuses much more rapidly than O<sub>2</sub>, as its diffusion coefficient is 20 times higher.<sup>6</sup> This is of no consequence under normal conditions; however, if the surface area for diffusion decreases or the tissue thickness increases, O<sub>2</sub> delivery can be negatively impacted. In that case, the patient can become hypoxemic due to decreased oxygen saturation before they become hypercapnic due to decreased elimination of CO<sub>2</sub>.

Oxygen within the blood can be transported in a dissolved state or as a reversible combination with hemoglobin called oxyhemoglobin.<sup>2,7</sup> Approximately 98.5% of the oxygen delivered to peripheral tissues is bound to hemoglobin.<sup>2</sup> Oxygen-carrying capacity refers to the maximum amount of oxygen that can be bound by hemoglobin when all available binding sites are occupied. Oxygen saturation, on the other hand, refers to the amount of O<sub>2</sub> bound to hemoglobin divided by the oxygen-carrying capacity. In other words, oxygen saturation reveals the proportion of binding sites occupied by O<sub>2</sub>.

The oxygen-hemoglobin dissociation curve has a unique sigmoidal shape. The flat upper part indicates that when  $\text{PaO}_2$  is greater than or equal to 80 mmHg, a decrease in the partial pressure of alveolar gas has very little effect on oxygen saturation. Under these conditions, there is a large enough reserve of  $\text{O}_2$  for it to diffuse into the blood and saturate the hemoglobin. The steep portion of the curve indicates that peripheral tissues can remove a large amount of  $\text{O}_2$  resulting in a relatively small decrease in capillary  $\text{PaO}_2$ .

A rightward shift in the oxygen-hemoglobin dissociation curve indicates better unloading of  $\text{O}_2$ , which benefits peripheral tissues.<sup>2,7</sup> Causes of a rightward shift include acidosis, increased temperature, increased 2,3-diphosphoglycerate (2,3-DPG) in red blood cells, and increasing  $\text{CO}_2$ . The reverse is also true, with alkalosis, decreased temperature, decreased 2,3-DPG, and decreased  $\text{CO}_2$  causing a leftward shift. Carbon monoxide (CO) has a remarkable affinity for hemoglobin, approximately 240 times that of  $\text{O}_2$ . Even small amounts of CO can occupy large amounts of hemoglobin, making it unavailable to carry  $\text{O}_2$ . Therefore, the presence of CO causes a leftward shift as well, hindering the unloading of  $\text{O}_2$  in peripheral tissues.

$\text{CO}_2$  can be carried three different ways.<sup>2,7</sup> Approximately 5% of transported arterial  $\text{CO}_2$  is carried in the dissolved form. Approximately 20% of excreted  $\text{CO}_2$  is carried in combination with proteins (principally hemoglobin) as carbamino compounds. The majority of  $\text{CO}_2$ , however, is transported as bicarbonate ( $\text{HCO}_3^-$ ). The enzyme carbonic anhydrase catalyzes the reaction of  $\text{CO}_2$  and water ( $\text{H}_2\text{O}$ ) to produce carbonic acid ( $\text{H}_2\text{CO}_3$ ). Carbonic acid then dissociates into  $\text{HCO}_3^-$  and  $\text{H}^+$ , as shown below.



Bicarbonate then diffuses back into the plasma along a gradient. Because the cell membrane is relatively impermeable to cations,  $\text{H}^+$  gets trapped in the red blood cell. Chloride ( $\text{Cl}^-$ ) and  $\text{H}_2\text{O}$  diffuse back into the cell to maintain electroneutrality and osmotic balance. Hemoglobin buffers the  $\text{H}^+$ , and the reaction continues moving to the right; however,  $\text{CO}_2$  is removed in the lungs through ventilation, which decreases  $\text{PaCO}_2$ , moving the reaction back to the left.

Deoxygenated blood carries more  $\text{CO}_2$  than oxygenated blood due to the greater affinity of deoxygenated hemoglobin for  $\text{CO}_2$  compared to oxyhemoglobin. This is known as the Haldane effect, which describes the effect of changes in oxyhemoglobin saturation on  $\text{CO}_2$  content in relation to  $\text{PCO}_2$ .<sup>2</sup>

The exchange of gases between alveolar gas and arterial blood relies on the ratio of ventilation to perfusion.<sup>2,8</sup> For adequate exchange of  $\text{O}_2$  at this level, ventilation of the alveoli ( $V$ ) must match the blood flow ( $Q$ ), or perfusion to the area, such that  $V/Q=1$ . Situations when this does not occur induce a  $V/Q$  mismatch. A pulmonary thromboembolism causes a high  $V/Q$ , as the perfusion to some ventilated alveoli is decreased. On the other hand, atelectasis, pneumonia, and severe pulmonary edema cause a low  $V/Q$ , because the perfused alveoli are not well ventilated.

Hypoxemia is defined as arterial saturation of oxygen less than 90%. This can be caused by hypoventilation, a low fraction of inspired oxygen, diffusion impairment, shunts or venous admixtures, and  $V/Q$  mismatches. Hypoventilation is indicated by an increased  $\text{PaCO}_2$ . A low fraction of inspired oxygen means that there is an increase in  $\text{CO}_2$  or other gases in the inspired air. Diffusion impairment occurs with an increase in

tissue thickness or decrease in the surface area of the blood-gas interface within the alveolar membrane. This typically means that severe changes have occurred within the lungs. Anatomic shunts or venous admixtures occur when deoxygenated blood enters the arterial system without first going through ventilated lung. V/Q mismatches, as previously mentioned, indicate disproportionate ventilation and perfusion within the lung. Patients experiencing hypoventilation, low fraction of inspired oxygen, and diffusion impairments respond well to supplemental oxygen. Patients with a high V/Q mismatch may also have a good response. However, patients with a low V/Q mismatch typically have a very limited response, and patients with shunts have a poor response to supplemental oxygen.

### **1.3. Canine Surgical Pulmonary Disease**

Canine pulmonary diseases often have similar or overlapping clinical signs. These signs may range from lethargy, inappetence, and exercise intolerance, to severe dyspnea, physiologic compromise, and imminent death. Many pulmonary diseases result in a cough, but others may be completely asymptomatic or subclinical for a period of time.

#### *1.3.1. Diagnostic tests*

Once a suspicion of respiratory disease has been triggered, a series of diagnostic tests can help prioritize differentials. Standard blood work (complete blood count and serum biochemistry panel) may help shed light on the systemic health of the patient. Animals with infectious pulmonary diseases may have inflammatory leukograms with a left shift; however, these tests are not considered especially sensitive or specific for pulmonary diseases.

Blood gas analysis provides more data on acid-base status and oxygenation compared to a serum biochemistry panel. Specifically, the  $pO_2$  and  $pCO_2$  are reported. Arterial samples are generally most useful for patients with respiratory disease, as venous samples are affected by tissue metabolism. Venous blood is typically more acidic and has a lower oxygen content. Within an arterial sample, high and low  $pO_2$  measurements indicate blood hyperoxia and hypoxia, respectively. High and low  $pCO_2$  measurements indicate hypoventilation and hyperventilation, respectively. Hypoventilation is compatible with a respiratory acidosis, while hyperventilation is compatible with a respiratory alkalosis. While this can be useful information to assess current respiratory function and for continued monitoring, blood gas changes are not typically specific to one disease process. Therefore, further diagnostics are generally required.

Serial radiographs serve an important role in diagnosing and monitoring progression of disease. In cases of severe respiratory compromise due to pleural effusion or pneumothorax, it is essential to remove the fluid or air within the pleural space via thoracentesis prior to radiographs both for stability of the patient as well as improved visualization of the cardiovascular structures. Cytology, fluid analysis, and cultures of material collected by thoracentesis are necessary to further characterize pleural effusion. Advanced imaging such as computed tomography (CT) and magnetic resonance imaging (MRI) can also be useful for evaluation of the nasopharyngeal, tracheal, and thoracic structures. CT and MRI are typically more expensive, normally require general anesthesia, and are not as readily available as plain film radiography; however, they often provide more information regarding the pathogenesis and extent of



the disease state. The rapid speed of image acquisition with CT is valuable as artifact from respiratory and cardiac motion can interfere with image quality on MRI. CT has higher sensitivity for identification of smaller lesions, minimizes artifact, and allows the viewing of images in axial, coronal, or sagittal planes compared to radiography.<sup>9</sup> For these reasons, thoracic radiographs may be used as a first-line modality for pulmonary disease. In many cases though, CT is necessary to further characterize the lesion and determine the best course of treatment.

Tracheobronchoscopy involves the passage of a small camera with an instrument portal into the airways. This allows diagnosis of many structural diseases, inflammatory conditions, and traumatic injuries. Tracheobronchoscopy can be used alone or can be combined with brush cytology, forceps biopsy, bacterial culture, transbronchial lung biopsy, transbronchial needle aspiration, foreign body removal, and bronchoalveolar lavage.

Bronchoalveolar lavage is a diagnostic tool that can be utilized to identify specific disease processes in the lungs. This involves instilling sterile saline into the small airways under bronchoscopic guidance in an attempt to bathe the alveoli supplied by that airway. The resultant fluid, comprised of saline and cellular and acellular material lining the epithelial surface, is then quickly removed with suction. The fluid can be submitted for evaluation by cell cytology, culture, PCR, virus isolation, or specific antigen assays for characterization of pulmonary disease.<sup>10</sup>

Thoracoscopy can be used as another minimally invasive diagnostic tool. Exploratory thoracoscopy has been used as a purely diagnostic procedure and in conjunction with therapeutic procedures as well. Exploratory thoracoscopy has been

used for the diagnosis and/or treatment of pleural disease, spontaneous pneumothorax, pyothorax with or without foreign bodies, chylothorax, diaphragmatic hernia, lung lobe torsion, intrathoracic masses or enlarged lymph nodes, staging of intrathoracic neoplasms, and pericardial disease.<sup>11</sup>

Importantly, these diagnostics all serve different purposes in the workup of patients with respiratory diseases. Baseline workup typically includes blood work and imaging studies. Based on information gleaned from these tests, the remaining diagnostics can be prioritized. Many patients with severe respiratory compromise are not stable anesthetic candidates on initial presentation and require medical therapy for a period of time before anesthetized diagnostics such as CT, bronchoscopy, or thoracoscopy can be undertaken. Once a definitive diagnosis is made, a treatment plan can be individualized based on the disease process and clinical status of the patient.

### *1.3.2. Pulmonary diseases*

#### *1.3.2.1. Pulmonary cysts, bullae, blebs, and pneumatoceles*

Pulmonary cysts, bullae, and blebs are thin-walled cavities within the lung parenchyma. Cysts may be filled with air or fluid and are defined by their distinct lining of respiratory epithelium. They are typically caused by blunt trauma, most commonly in younger animals. If infected, pulmonary cysts may progress to a pneumatocele or abscess with destruction of the epithelial lining. Bullae and blebs, in contrast, have no epithelial lining and are air-filled. A bulla is defined as an abnormal air space within the pulmonary parenchyma. A bleb is an abnormal air space between the parenchyma and the visceral pleura. Bullae and blebs typically occur secondary to obstructive lung

disease, where there is traumatic rupture and coalescence of the alveoli in the affected tissue. Similar to cysts, these can progress to abscesses if there is a source of infection. If these structures rupture, pneumothorax can result. Cysts, bullae, blebs, and pneumatoceles are usually not seen on radiographs, as atelectasis of the lobe may occur making pneumothorax the only visible abnormality.<sup>2</sup> CT has been recommended for the diagnosis of these cases, with a reported sensitivity of up to 75%, compared to the sensitivity of radiography (<5-50%).<sup>9</sup> Conservative management may be attempted for 2-3 days with indwelling thoracostomy tubes, chest drainage systems, and/or pleurodesis as needed. Specifically, autologous blood-patch treatment has been utilized for patients with persistent pneumothorax, with a reported success rate of 62.5% after one procedure and 87.5% after subsequent procedures.<sup>12</sup> In cases when conservative management fails, the treatment of choice includes a partial or total lung lobectomy of the involved lung lobes. Many dogs have more than one lesion, and lesions may occur bilaterally. If disease occurs bilaterally, a median sternotomy is the preferred approach to be able to assess all lung fields.<sup>2</sup> The thoracic cavity may be filled with sterile saline to help in identification of the inciting lesion. Once identified, the surgeon may perform a partial or total lung lobectomy. Histopathology and cultures are recommended. As an alternative to an open approach, thoracoscopy may be performed to explore the thorax prior to lobectomy, but it can be difficult to visualize the entire lung surface. Pleurodesis can also be attempted intra- or postoperatively to cause pleural adhesions and decrease the risk of recurrence.

#### *1.3.2.2. Bronchoesophageal fistulae*

Bronchoesophageal fistulae are very rare conditions in young to middle-aged dogs. The most common cause is proposed to be an esophageal foreign body that perforates or causes pressure necrosis of the esophagus. A fistula may develop between the esophagus and the adjacent lung or airway. Saliva and food can then migrate into the lung parenchyma and cause pneumonia. Contrast thoracic radiography can be performed using a small amount of barium administered orally. Iodinated aqueous products are not recommended, as they are hyperosmolar compared to the lung and may cause pulmonary edema.<sup>9</sup> A better way to diagnose bronchoesophageal fistulae is esophagoscopy to identify the location and size of the fistula. The treatment of choice includes debridement and closure of the esophageal defect and lobectomy of the lung supplied by the affected bronchus. With early identification and treatment, prognosis can be good. If the fistula is not identified and treated promptly, aspiration pneumonia and/or esophageal stricture may occur secondarily.

#### *1.3.2.3. Consolidation and abscessation of lung lobes*

Consolidation of a lung lobe can occur secondary to a foreign body, bacterial or fungal infection, parasites, or neoplasia. Abscessation of a lung lobe may occur secondary to a penetrating thoracic wound into the lung lobe, vascular obstruction, or central necrosis of pulmonary neoplasia. Rupture of an abscess can subsequently lead to pyothorax. Thoracic radiographs can be helpful to localize the region and CT can potentially help identify a foreign body, if present, or further localize the lesion. Bronchoalveolar lavage can be performed to collect samples for cytology as well as culture and sensitivity. The most common bacterial causes of lung lobe abscesses

include *Escherichia coli*, *Klebsiella pneumoniae*, *Staphylococcus* spp., *Streptococcus* spp., *Pseudomonas* spp., and *Fusobacterium* spp., *Nocardia* spp. and *Corynebacterium* spp. are also common pathogens in cats. Medical management is generally recommended prior to surgery. Appropriate medical therapy includes antibiotic coverage for at least 2-3 weeks. A thoracostomy tube may also be placed with or without pleural lavage. If the patient does not respond to medical management within one week or if the patient worsens, surgery may be indicated. A partial or total lobectomy may be performed to excise the affected tissues. Sheets of fibrin may be encountered and should be debrided, as they can harbor bacteria. A thorough lavage of the surgical field should be performed. A thoracostomy tube may be placed at the time of surgery prior to closure to remove residual air and fluid immediately postoperatively and monitor for continued air leakage or fluid production.

#### 1.3.2.4. *Bronchiectasis*

Bronchiectasis refers to the destructive lung disease that leads to severe airway dilatation. The disease process is primarily due to the production of proteolytic enzymes and cytokines by inflammatory cells that destroy the elastic and muscular portions of the bronchi, resulting in severe, permanent bronchial dilation, the inability of bronchi to constrict normally, and the destruction of both normal glandular cells and the mucociliary apparatus.<sup>2,13</sup> This leads to the accumulation of secretions and recurrent bronchial infections. The damage to the lung may be focal or diffuse. If it is localized to a focal region of the bronchial wall, it will appear sacculated. If the whole bronchial wall is affected, it will appear cylindrical. Breeds with reported predispositions include the American cocker spaniel, West Highland white terrier, miniature poodle, English

springer spaniel, Siberian husky, and Shetland sheepdog. The disease process can be related to primary ciliary dyskinesia or chronic respiratory disease. Thoracic radiographs with or without contrast bronchography may help obtain the diagnosis. Bronchoscopy and CT can be considered if the radiographs fail to detect the lesion. If bacterial bronchitis is suspected, a bronchoalveolar lavage to obtain samples for aerobic and anaerobic cultures is indicated. For focal disease, a partial or total lung lobectomy can be considered to eliminate the focus causing recurrent infections. For more generalized disease, surgery is not useful. Following surgery, these patients must be monitored closely for respiratory infections and have a guarded prognosis.

#### *1.3.2.5. Lung injuries*

Lung injuries typically result from blunt or penetrating trauma to the thorax. Wounds resulting from automotive collisions and animal attacks are common causes of lung injury, which can lead to lung lobe laceration and resultant pneumothorax. The force of the trauma may also result in contusions which may not be readily apparent but will aggravate the clinical status of the patient. Radiographic evidence of lung contusions is often delayed by 24-48 hours. Blunt trauma commonly results in rib fractures. Rib fractures can then lacerate lung lobes. Another suggested cause of lung lobe injury following blunt trauma is rupture following lateral compression of the thoracic wall with a closed glottis. In this scenario, the rupture is explosive in nature as there is a rapid increase in airway pressure. Other less common causes of lung lobe injury include migrating foreign bodies, such as grass awns or porcupine quills, and iatrogenic laceration during needle aspiration of intrathoracic structures, percutaneous thoracostomy tube placement, or thoracocentesis. In cases of trauma, thoracic

radiographs may show bilateral pleural effusion or pneumothorax. Visible rib fractures may help to determine the side of impact. Small lacerations may heal without surgical intervention. A thoracostomy tube may be used to remove intrapleural air or blood. These cases may still need substantial care for lung contusions or other trauma. Autologous blood patches are reportedly more successful for traumatic causes of pneumothorax than for nontraumatic causes and can be considered.<sup>14</sup> Surgery is indicated in patients that continue to have a pneumothorax beyond 3-4 days. If the side of the injury is known, an intercostal thoracotomy is appropriate. However, if the location of the injury is not known or if lesions are bilateral, a median sternotomy is recommended. The thoracic cavity can be filled with sterile saline to identify potential air leaks. Peripheral lacerations can be closed with a mattress pattern. If the tissue is friable, Teflon pledgets can be used to help provide a seal without tearing the tissue. Deeper lacerations may leak copiously if an airway has been damaged. In patients with lacerations in peripheral lung tissue, a partial lung lobectomy may also be performed. If the injury is hilar, the airway can be reapposed with simple interrupted sutures. The lacerated parenchyma may then be closed as above. A leak test should be performed. A thorough lavage of the surgical field should also be performed, and samples for culture may be taken depending on the inciting cause of injury. A thoracostomy tube may be placed prior to closure to remove residual air and fluid immediately postoperatively and monitor for continued air leakage or fluid production.

#### *1.3.2.6. Lung lobe torsions*

Lung lobe torsions occur most commonly in large, deep chested dogs such as Afghans, cats, Yorkshire terriers, and pugs.<sup>2,15,16</sup> Torsions may occur spontaneously or

secondary to other thoracic diseases. Pugs seem to be at an increased risk for spontaneous lung lobe torsion and may have a more favorable prognosis.<sup>2</sup> Lung lobe torsions typically occur at the hilum along the long axis, causing obstruction of the vein, lymphatics, and bronchus, without obstruction of the artery. This results in edema, hemorrhage, and necrosis within the lobe. Pleural effusion results from the pulmonary venous hypertension and decreased lymphatic drainage. Removal of pleural effusion can help localize the lesion on radiographs or CT. If the location of the affected lobe is known, an intercostal thoracotomy may be performed to facilitate lung lobectomy. The lobectomy should be performed without untwisting the lobe to prevent release of inflammatory cytokines and endotoxins into the systemic circulation.

#### *1.3.2.7. Pulmonary neoplasia*

Primary pulmonary neoplasia accounts for approximately 1% of all tumors in dogs.<sup>2</sup> Primary tumors are much less common than metastatic neoplasia in the lungs. The vascular bed within the lungs receives most of the right cardiac output with each cardiac cycle.<sup>9</sup> Because the capillary beds within the lungs receive all of this blood, the lungs are a perfect location for metastatic lesions to develop. Almost any type of neoplasia can metastasize to the lungs, but oral and nail bed melanomas, thyroid carcinomas, osteosarcomas, and mammary carcinomas are most common.<sup>9</sup> Primary lung tumors are typically malignant in nature, and most are carcinomas of bronchial or alveolar origin. Other types of primary lung tumors include squamous cell carcinoma, histiocytic sarcoma, and anaplastic tumors. As the tumor invades into the tissue, vessel or airway destruction can result in hemorrhage or pneumothorax, respectively. Animals with pulmonary tumors (primary or metastatic) can also suffer from hypertrophic



osteopathy as a paraneoplastic syndrome.<sup>2</sup> These patients can have extensive long bone periosteal proliferation and painful extremities. Thoracic radiographs are often sufficient for the identification of large tumors; however, tumors <8-9 mm can be difficult to visualize due to summation artifact.<sup>9</sup> CT is more sensitive for the identification of small masses, including metastatic disease, as well as invasion into surrounding structures such as vasculature, and should be considered prior to surgical intervention. The definitive diagnosis of pulmonary neoplasia involves histologic or cytologic identification of neoplastic cells. Fine needle aspirates of large peripheral lung tumors can provide a diagnosis in up to 80% of samples with a sensitivity of 77% and specificity of 100%.<sup>12</sup> The diagnosis including the specific cell type is correct in 82% of cases.<sup>12</sup> Complications of fine needle aspiration include pneumothorax, hemoptysis, and death, and can be minimized using ultrasound guidance and small gauge (22 or 25 gauge) needles.<sup>12,17</sup> Treatment of choice for neoplasia confined to one lobe is total lobectomy. Survival times in dogs are correlated with histologic cell type, tumor size, presence of metastasis, presence of pleural effusion, and clinical signs.<sup>2</sup> More specifically, positive prognostic indicators include complete tumor removal, the presence of a single tumor without metastasis, a lack of clinical signs, a lower histologic grade or more well-differentiated tumor, a peripherally located tumor, and the absence of pleural effusion.<sup>9</sup>

Metastasectomy is somewhat controversial but may be useful in cases where 1-2 metastatic nodules occur long after treatment of the primary tumor. Previously, recommendations for consideration for metastasectomy for dogs with stage III appendicular osteosarcoma included a disease-free interval of greater than 300 days and the presence of less than three metastatic pulmonary nodules.<sup>18</sup> However, in this

study, there was no control group with which to compare the results of metastasectomy. In another study of similar patients, there was no difference in survival times between dogs that underwent metastasectomy and those that did not.<sup>19</sup> In the most recent study, patients receiving metastasectomies survived significantly longer than those that did not.<sup>20</sup> The role of disease-free interval was challenged in this study, as it was not significantly associated with survival time. More data is needed to help clarify the role of metastasectomy in oncologic patients as well to determine which patients are the best candidates for such procedures.

#### **1.4. Canine Lung Surgery**

The most common canine lung surgeries include partial and total lung lobectomy of a single lung lobe and pneumonectomy (removing all lobes in one hemithorax). Following all open procedures, the thoracic cavity is filled with warm sterile saline. The remaining lungs or stumps are submerged, and positive pressure ventilation is provided to supraphysiologic pressures of 25 to 30 cm H<sub>2</sub>O. Leaks can be identified by gas bubbles visible within the fluid and may be closed with additional sutures. Small leaks such as from needle tracts may be closed by suturing surrounding pleural and subpleural tissue over the cut edge of bronchi or vessels. Thoracostomy tube placement is recommended for postoperative removal of air or fluid. Once the production of air has ceased, and the production of fluid has tapered, the thoracostomy tube can be removed, often within 24 hours.

### *1.4.1. Surgical approaches for canine lung surgery*

#### *1.4.1.1. Intercostal thoracotomy*

Access to the canine lungs is often performed using a fourth or fifth intercostal thoracotomy. The patient is placed in lateral recumbency with the affected side uppermost and the upper extremity secured in an extended position. The skin and subcutaneous tissue are incised approximately 2 cm caudal to the scapula. The latissimus dorsi muscle may be incised or retracted dorsally. The intercostal spaces may be counted and confirmed deep to this muscle. The caudal border of the scalenus muscle usually inserts on the fifth rib and can serve as another way to confirm identification of the appropriate intercostal space. Muscle bellies from the serratus ventralis inserting on the rib caudal to the selected intercostal space must be elevated and retracted cranially. The external and internal intercostal muscles must then be incised, taking care to avoid the neurovascular bundle coursing along the caudal aspect of the rib cranial to the intercostal space. The pleura, if still intact, may then be gently punctured to prevent damage to the underlying lungs during the remainder of the entry into the thoracic cavity. The intercostal thoracotomy may be extended dorsally to the point where the ribs angle medially to prevent damage to the epaxial musculature. The incision may be extended ventrally to the lateral aspect of the transverse thoracic muscle. This ventral landmark should preserve the internal thoracic artery. The internal thoracic artery may also be palpated digitally, and care should be taken as the incision is extended ventrally to protect this structure. Closure involves circumcostal sutures or transcostal sutures utilizing bone tunnels in the caudal rib to approximate the ribs, followed by routine closure of the muscle bellies, subcutaneous tissue, and skin.

This approach is appropriate for procedures within a specific region of the thoracic cavity and the laterality of the disease is known. Generally, structures in the vicinity of the thoracotomy are easily accessible. However, there is limited to no access to the contralateral hemithorax.

#### *1.4.1.2. Median sternotomy*

Median sternotomy may be performed to provide access for canine lung surgery. The patient is positioned in dorsal recumbency with the forelimbs secured caudally. A ventral midline skin and subcutis incision is performed, followed by separation of the pectoral muscles along the sternbrae. The sternbrae are then carefully sectioned along midline using an oscillating saw or osteotome and mallet. If possible, preservation of either an intact manubrium or xyphoid may help provide stability upon closure. Closure involves figure of eight sutures or cerclage wires around the sternbrae.<sup>21</sup> Stainless steel wire is favored in most cases, especially in large breed dogs, to achieve better stability and minimize displacement.<sup>22</sup> This is followed by routine closure of the pectoral muscles, subcutaneous tissue, and skin.

This approach allows exploration of the entire thoracic cavity and is useful in control of disease that is bilateral or when the laterality is unknown. Access to structures in the dorsal thoracic cavity may be more difficult compared to access achieved with an intercostal thoracotomy.

#### *1.4.1.3. Keyhole approach*

The keyhole approach is a less invasive option that utilizes a Finochietto rib retractor through a small intercostal thoracotomy (3-7 cm long).<sup>2</sup> The affected lung lobe

can be retracted atraumatically through the thoracotomy, and a sample can be obtained via suture ligation or stapling device as described previously. This approach may be useful for generalized interstitial lung disease in cases where a thoracoscope is not available, or when small patient size precludes the use of thoracoscopy.

#### *1.4.1.4. Thoracoscopic and thoracoscopic-assisted approaches*

If a thoracoscope is available, a completely thoracoscopic or thoracoscopic-assisted approach can be used for peripheral biopsies and for partial and total lung lobectomies.<sup>23,24,25</sup> A partial lung lobectomy may be performed using a pretied ligature loop, which avoids the need for intracavitary knot tying. The loop is passed through a cannula, and grasping forceps are utilized to pass the affected tissue through the loop. The loop is tied, and the tissue is transected distal to the ligature using endoscopic Metzenbaum scissors. The suture tag is cut with endoscopic hook scissors. Biopsy of lung tissue no more than 3 cm from the tip of the lobe is recommended to avoid air leakage and hemorrhage.<sup>2</sup>

For a thoracoscopic-assisted procedure, an additional cannula is placed at the intercostal space adjacent to the lesion. Atraumatic grasping forceps are placed through the cannula to grasp the tip of the lung lobe containing the affected tissue. The cannula thoracotomy is enlarged, and the tissue is partially exteriorized to perform an extracorporeal partial or total lobectomy.

If a thoracoscopic approach is utilized, one-lung ventilation allows more working space within the thorax and may be considered.<sup>23</sup> Briefly, one-lung ventilation involves the ventilation of the unaffected lung lobes while blocking the inflation of the affected

lung lobe or hemithorax. This improves visualization of the surgical site and theoretically reduces the risk of iatrogenic injury to the surrounding tissues.

#### *1.4.2. Partial lung lobectomy using hand suturing*

Partial lung lobectomy refers to amputation of the distal 2/3 or less of the lung lobe for isolated disease or to obtain diagnostic samples. Indications for this procedure include but are not limited to lung abscesses not responsive to medical management, cysts or bullae, small peripheral tumors, and peripheral lacerations. With peripheral lesions, a distal lobe amputation may be utilized. For this procedure, crushing forceps are placed across the lung lobe at the desired level. If a wedge of tissue is removed, two forceps may be used to isolate the wedge. A continuous overlapping hemostatic-pneumostatic suture pattern is placed proximal to the crush of the forceps. The lung tissue is transected just proximal to the forceps. The cut edge of the lung is then oversewn in a simple continuous pattern. Relatively large bronchi or vessels encountered during this procedure should be individually ligated to reduce air leakage or hemorrhage.

#### *1.4.3. Total lung lobectomy using hand suturing*

In contrast to partial lung lobectomy, total lung lobectomy refers to removal of the entire lung lobe. The pulmonary vessels and lobar bronchus supplying the affected lung lobe must be identified and isolated. Other lung lobes may be retracted with saline moistened laparotomy sponges, and the pulmonary ligament anchoring the caudal lung lobes transected as needed to allow increased mobilization of the lobe. The pulmonary artery is typically approached first to prevent congestion of the lobe and reduce the risk

of severe hemorrhage as the dissection is continued. Right-angle forceps aid in isolation of the artery, especially on the blind medial side of the vessel. Once adequate dissection is complete, the artery is ligated. The pulmonary vein is then approached on the caudal or ventral aspect of the bronchus. The lobe may be retracted dorsally to aid in visualization. The vein is double or triple ligated and transected between ligatures. The main lobar bronchus is then dissected from surrounding tissue and cross clamped proximal and distal to the desired transection site. The bronchus is transected between the two forceps and the lung is removed to allow more working space within the thorax. Preplaced interrupted horizontal mattress sutures are placed just proximal to the remaining pair of forceps. When the sutures are tied, collapse of the bronchus is noted. The bronchus is transected just distal to the suture line. The cut edge of the bronchus is typically oversewn using a simple continuous pattern.

#### *1.4.4. Pneumonectomy*

Pneumonectomy involves removal of the lung lobes in one hemithorax. The left and right sides of the lung comprise 42% and 58% of the total lung volume, respectively.<sup>26</sup> A recent study validated right-sided pneumonectomy in clinical patients, as acute removal of more than 50% of the lung volume was previously thought to be poorly tolerated.<sup>26</sup> In this study, 3/5 patients undergoing a right pneumonectomy survived to discharge. The two patients that died prior to discharge were euthanized due to declining respiratory function and financial constraints. One of the two developed aspiration pneumonia postoperatively, which may have contributed to the declining status. Staged lobectomies may allow even more of the total lung volume to be removed. When lobectomies were staged over a period of 6 months, dogs without

pulmonary disease were able to tolerate removal of all but the equivalent of 1.5 caudal lung lobes.<sup>2</sup> Following pneumonectomy, as an attempt to restore normal lung capacity, the lung will regenerate to some degree. To do so, a hyperplastic response occurs, with increases in the alveolar, bronchial, and vascular components. Secondary changes also occur in the contralateral lung and myocardium. As the lung regenerates, a simultaneous decrease in compliance, vital capacity, and perfusion occurs. The right ventricle hypertrophies, and increases in pulmonary vascular resistance and residual lung capacity have been identified.<sup>27</sup> The remaining lung has been noted to be more sensitive to positive end expiratory pressure, as increased pulmonary vascular resistance has been noted at a given level of positive end-expiratory pressure.<sup>28</sup> This has been correlated with decreased cardiac output. A compensatory improvement in the transport of O<sub>2</sub> has been noted after >50% pneumonectomy. This occurs due to several factors including recruitment of physiologic reserves of diffusion capacity, remodeling of the existing alveolar-capillary structures, and growth of new alveolar-capillary units.<sup>29</sup>

As hilar dissection begins, the sequence of vessel and bronchus ligation typically resembles that of a lobectomy. Early control of the supplying branch of the main pulmonary artery, or lobar artery, is recommended. This decreases the risk of severe hemorrhage as dissection continues. This vessel should be triple ligated, as described for a lobectomy. If the vessel is larger than 5 mm in diameter, it should be stapled or the cut edge should be oversewn with a double layer of simple continuous pattern.<sup>2</sup> Veins are ligated similarly. The endotracheal tube should be deflated, advanced into the contralateral bronchus, and reinflated prior to ligation and transection of the affected bronchus. The affected bronchus should be transected and occluded using interrupted



horizontal mattress ligatures. The cut edge is oversewn with a simple continuous pattern.

#### *1.4.5. Stapling options for canine lung surgery*

Stapling devices may be used as an alternative to sutures in patients that are large enough. The TA™ (thoracoabdominal) Stapler (Medtronic, Minneapolis, MN), as shown in Figure 1, is widely used. The TA™ stapler deploys two or three staggered rows of titanium staples to seal tissue, with a cutting groove along the side of the device used as a guide for transection of the tissue distal to the staples after staple deployment. Multiple studies have validated the TA™ stapler for use in animal lung lobectomies.<sup>30,31,32</sup> Benefits of using the TA™ stapler include its ease of application and rapid firing, especially compared to the time required for performing hand suturing. However, the size and inflexibility of this device restricts its maneuverability within the thorax, especially in small patients. Therefore, its use in minimally invasive procedures is limited to those that can be completed via extracorporeal firing of the stapler through a mini-thoracotomy. The stapler does not incorporate a blade to transect the tissue; therefore, a scalpel or scissors must be introduced separately once the stapler has been fired. Since the staples deploy on only one side of the transection line, another instrument such as a hemostat must be introduced separately to clamp the tissue to be transected in cases where backflow of cells into the thorax may be detrimental to the patient.



Figure 1. TA™ stapler.

TA™ staple cartridges come in 30 mm, 45 mm, 60 mm, and 90 mm lengths.<sup>33</sup> The 30 mm cartridge length is available with 2.5 mm (white V3 vascular cartridge), 3.5 mm (blue cartridge), or 4.8 mm staple heights (green cartridge). These staples compress to 1.0, 1.5, and 2.0 mm respectively. The 45 mm, 60 mm, and 90 mm cartridges are available with 3.5 mm or 4.8 mm staple heights.

Another stapling device option is the GIA™ (gastrointestinal anastomosis) Stapler (Medtronic, Minneapolis, MN). The GIA™ staple cartridge deploys three staggered rows of titanium staples on each side of a blade that transects the tissue as the staples are deployed. The GIA™ stapler was initially designed for gastrointestinal surgery but is now also used in human and veterinary thoracic surgery. Benefits of its use are similar to those of the TA™ stapler, with the additional benefits of an incorporated blade to transect the tissue and staples on both sides of the transection line to limit the spread of disease from backflow of cells within the transected tissue. This stapler is a relatively sizable and inflexible device within the small working space of the thorax, which limits its maneuverability.

GIA™ staple cartridges come in 60 mm, 80 mm, and 100 mm lengths.<sup>33</sup> The 60 mm cartridges are available with 2.5 mm (white cartridge), 3.8 mm (blue cartridge), or 4.8 mm staple heights (green cartridge). These staples compress to 1.0, 1.5, and 2.0 mm respectively. The 80 mm and 100 mm cartridges are available with the 3.8 mm or 4.8 mm staple heights.

For partial lung lobectomy using either the TA™ or GIA™ stapler, the stapler of appropriate size is placed across the lung lobe proximal to the lesion and fired. Stapled lobectomies are currently performed more commonly than hand sutured lobectomies with the benefits of decreased procedure time, minimal complications, the ability to remove multiple lesions or lesions that are difficult to resect with traditional techniques, and the ability to be used in a minimally invasive approach.<sup>23,24,25,30,31,34,35</sup>

Total lung lobectomies may be performed using the same stapling devices utilized in partial lung lobectomies. Staple heights of 2.5 and 3.5 mm are most commonly used with the TA™ stapler. The GIA™ stapler may also be utilized; the 60 mm cartridge length with 3.5 mm staple height has been recommended previously.<sup>31,34</sup> The stapler is placed across the hilus and deployed.

The Endo GIA™ (endoscopic gastrointestinal anastomosis) Ultra Universal Stapler (Medtronic, Minneapolis, MN) allows for a completely thoracoscopic surgical procedure. Similar to the GIA™ stapler, the Endo GIA™ staple cartridge deploys three staggered rows of titanium staples on each side of a blade that transects the tissue as the staples are deployed. Lansdowne et al. reported its use in thoracoscopic lung lobectomies, where the lobectomy was completed using the Endo GIA™ device successfully in five of nine dogs.<sup>23</sup> In the remaining four dogs, the procedure was

converted to an open approach due to poor visibility. This stapler requires a 12 mm cannula, and an intercostal or transdiaphragmatic approach may be used. An articulating arm of the staple cartridge allows increased maneuverability within the thorax. The stapler is fired as in an open approach, proximal to the tissue to be removed. A staple height of 2.5 mm has been recommended for partial lung lobectomy.<sup>2</sup> To prevent contamination of the thoracic wall in cases of neoplasia, the excised tissue may be placed in a specimen retrieval bag prior to exteriorization. Mayhew et al. reported similar short-term outcomes for thoracoscopic and open lung lobectomies.<sup>24</sup> The authors recommended open approaches for dogs less than 10 kg or having tumors greater than 8 cm in diameter (175 cm<sup>3</sup>).

The Endo GIA™ staple cartridges come in 30 mm, 45 mm, and 60 mm lengths.<sup>33</sup> Gray cartridges, available in 45 mm length, contain staples that are all 2.0 mm in height, which compress to 0.75 mm. Tan cartridges, available in 30 mm, 45 mm, and 60 mm lengths, contain staples that are 2.0, 2.5, and 3.0 mm in height from the inner to the outer row, which compress to 0.75, 1.0, and 1.25 mm respectively. Purple cartridges, available in 30 mm, 45 mm, and 60 mm lengths, contain staples that are 3.0, 3.5, and 4.0 mm in height from the inner to the outer row, which compress to 1.25, 1.5, and 1.75 mm, respectively. Lastly, black cartridges, available in 45 mm and 60 mm lengths, contain staples that are 4.0, 4.5, and 5.0 mm in height from the inner to the outer row, which compress to 1.75, 2.0, and 2.25 mm respectively.



Figure 2. Endo GIA™ Ultra Universal Stapler.

No studies to date have recorded the normal size of bronchi or hilar vessels in a wide range of veterinary patients. Recommendations for staple sizes in canine lung surgery have been made largely based on successful use of certain cartridges in patients, but there is no objective data to suggest that the recommended sizes offer the greatest degree of occlusion of these structures.

#### 1.4.6. *Alternative devices for canine lung surgery*

More recently, alternative devices used for a partial lung lobectomy in dogs include various vessel-sealing devices (VSD) and a pre-tied ligature loop (PLL). The LigaSure™ bipolar VSD with the Atlas™ handpiece (Medtronic, Minneapolis, MN) was used successfully for peripheral lung biopsy in six healthy dogs.<sup>36</sup> No dog developed a significant postoperative pneumothorax; however, bursting pressures were not tested in that study. In a cadaveric study of the LigaSure™ Impact™ hand piece (Medtronic, Minneapolis, MN) the VSD was not considered safe or reliable for this procedure, as some of the samples leaked air at subphysiologic pressures.<sup>37</sup> The authors of that study noted that leaks seen at the center of the seal would have resulted in severe pneumothorax in clinical patients. The Caiman® VSD (B. Braun Vet Care GmbH,

Tuttlingen, Germany) was successfully used in partial lobectomies in cadavers without air leakage at physiologic airway pressures.<sup>38</sup> A PLL (Surgitie™, Medtronic, Minneapolis, MN) was found to be effective in forming a seal at the biopsy site of peripheral lung biopsies at airway pressures up to 30 cm H<sub>2</sub>O.<sup>37</sup> However, some of the samples had small leaks just proximal to the site, which the authors attributed to minor trauma from the advancement of the knot pusher.

Alternative devices used for total canine lung lobectomy include a pre-tied ligature loop, and a vessel-sealing device as described for partial lung lobectomies.<sup>38,39</sup>

## **1.5. Summary**

The canine respiratory tract, and the lungs in particular, are remarkably well suited for the purpose of ventilation, gas exchange, and gas transport. The normal anatomy provides an ideal environment for such tasks. However, when disease develops, inflammatory changes within the bronchi and pulmonary parenchyma alter the mechanisms. Systemic diagnostic workups in these patients should be completed. This may include blood gas evaluation, bronchoalveolar lavage, tracheobronchoscopy, thoracoscopy, and imaging such as thoracic radiographs and/or computed tomography. Magnetic resonance imaging can be performed in some cases but is not widely used for this purpose in veterinary medicine. Many pulmonary diseases can be successfully medically managed for a period of time prior to the need for surgical intervention. Surgery is indicated in patients that fail medical management or when the prognosis is shown to be better with surgery. Surgical lung diseases in canine patients include pulmonary cysts, bullae, and blebs; congenital anomalies such as bronchoesophageal fistulae; consolidated lung lobes and abscesses; severe, nonresponsive and focal

bronchiectasis; lung lacerations; lung lobe torsion; and neoplasia. Surgical options may include laceration repair, partial or total lung lobectomy, and pneumonectomy. Many of these procedures can be completed using minimally-invasive approaches, which have become standard-of-care in human medicine.

## CHAPTER 2. INVESTIGATION AND VALIDATION OF A NOVEL ENDOSOPIC GASTROINTESTINAL ANASTOMOSIS (ENDO GIA™) STAPLE CARTRIDGE FOR CANINE LUNG LOBECTOMIES <sup>1</sup>

### 2.1. Introduction

When assessing surgical staplers, the size of the staple is important. The height of the staple should be correlated to the thickness of the compressed tissue, which in lung lobectomies includes the hilar vessels and bronchus. If the staples are too large, hemorrhage or air leakage may result from the lumen of a vessel or bronchus. If the staples are too small, incomplete closure of the staple, and subsequent incomplete compression of the tissue, may occur.<sup>30,32</sup> Previously, staple sizes of 2.5 and 3.5 mm have been recommended for lung lobectomies in dogs.<sup>30,31,32</sup> The TA™ V3 cartridge (Medtronic, Minneapolis, MN) is commonly utilized, which contains three rows of staples 2.5 mm in height, all closing down to 1.0 mm in height. Until now, the smallest Endo GIA cartridge available contained staples 2.0 mm, 2.5 mm, and 3.0 mm in height from the inner row to the outer row.<sup>33</sup> These staples close to heights of 0.75 mm, 1.0 mm, and 1.25 mm, respectively. The 2.0 mm Endo GIA staple cartridge (Medtronic, Minneapolis, MN) contains three rows of titanium staples that are 2.0 mm in height, and each row has a closure height of 0.75 mm. This is important because the smaller staples could allow for more complete compression of the hilar vessels and bronchus, which could decrease the incidence of intra- and post-operative hemorrhage and air leakage. Because the stapling device compresses tissue on both sides of the transected tissue, it

---

<sup>1</sup> Published as: St Blanc AW, Csomos RA. Investigation and validation of a novel Endo GIA stapler for canine lung lobectomies. *Can Vet J.* 2021;62:1207-1210. PMID: 34728848; PMCID: PMC8543658.



could also decrease thoracic contamination in patients with neoplasia and infection. Additionally, use of the stapling device could decrease anesthetic time, surgical time, and hospitalization costs, as well as allow for a completely thoracoscopic surgical procedure given the small size of the handle arm and the articulating nature of the arm tip at the cartridge. This staple cartridge has not yet been validated for use in veterinary thoracic surgery.

## **2.2. Objectives and Hypothesis**

The primary objective of this study was to validate the use of the 2.0 mm Endo GIA™ stapler cartridge for lung lobectomies in canine cadavers. Secondary objectives included determining the incidence of air leakage and procedure time for lung lobectomy using the novel staple cartridge and comparing with air leakage and the procedure time for suture ligation. Our primary hypothesis was that the 2.0 mm Endo GIA™ stapler could be used successfully to perform lung lobectomies in canine cadavers. Our secondary hypotheses were that the procedure time would be significantly shorter for stapled lung lobectomies using the Endo GIA stapler compared to suture ligated lung lobectomies, but that there would be no significant difference in the incidence of air leakage between the two procedures.

## **2.3. Materials and Methods**

### *2.3.1. Subjects of Study*

Sixteen canine cadavers with a weight range of 18-27 kilograms (mean 21.9 kg, median 21.5 kg) were procured from local shelters. The sample size used for this study was determined using the following *a priori* information: an alpha=0.05, a power of 0.8, an expected difference in surgery time of 15 minutes, and a standard deviation in each

group of 10 minutes (16 lungs, eight in each group). The dogs were euthanized for reasons unrelated to this study, were acquired fresh, and procedures were performed within 6 hours of euthanasia. The cadavers were randomly assigned by lottery into two groups. Dogs assigned to Group 1 had lung lobectomies performed by suture ligation (SL) and dogs assigned to Group 2 had stapled lung lobectomies (ST). Exclusion criteria included gross pulmonary parenchymal pathology, but no cadavers required exclusion from the study population for this reason.

### *2.3.2. Procedure*

All dogs were placed in left lateral recumbency and intubated via a tracheostomy due to varying degrees of rigor mortis, with the cuff of the endotracheal tube inflated so that no leak was detected with positive pressure ventilation at 25 cm H<sub>2</sub>O prior to commencement of surgery. All dogs then underwent a right lateral thoracotomy at the fifth intercostal space. A Finochietto rib retractor was used to aid in exposure of the right hemithorax. The eight dogs in Group 1 (SL) then underwent a total right middle lung lobectomy using individual dissection, ligation, and transection of the hilar vessels and bronchus. The vessels were triple ligated separately, with two encircling ligatures of 2-0 monofilament absorbable suture (Maxon, Medtronic, Minneapolis, MN) proximal and distal, and one transfixation ligature in between. The vessels were transected between the two distal ligatures. The bronchus was ligated with three encircling ligatures using the same suture and was transected between the two distal ligatures. The bronchus stump was oversewn with 4-0 monofilament absorbable suture (Biosyn, Medtronic, Minneapolis, MN). The dogs in Group 2 (ST) underwent a total right middle lung lobectomy using the 2.0 mm Endo GIA™ stapler. The hilar vessels and bronchus were

identified, and the stapler was deployed perpendicular to the hilus. Once the assigned procedure was finished, the thoracic cavity was filled with water. Positive pressure ventilation was utilized to hold pressure at 20 cm H<sub>2</sub>O for 5 minutes to mimic maximum physiologic airway pressure.<sup>Bruckner</sup> The submerged bronchus was assessed for air leakage as evidenced by gas bubbles within the fluid. Inability to maintain positive pressure at 20 cm H<sub>2</sub>O was also considered to be the result of air leakage from the lung. All procedures were performed by the same surgery resident in training.

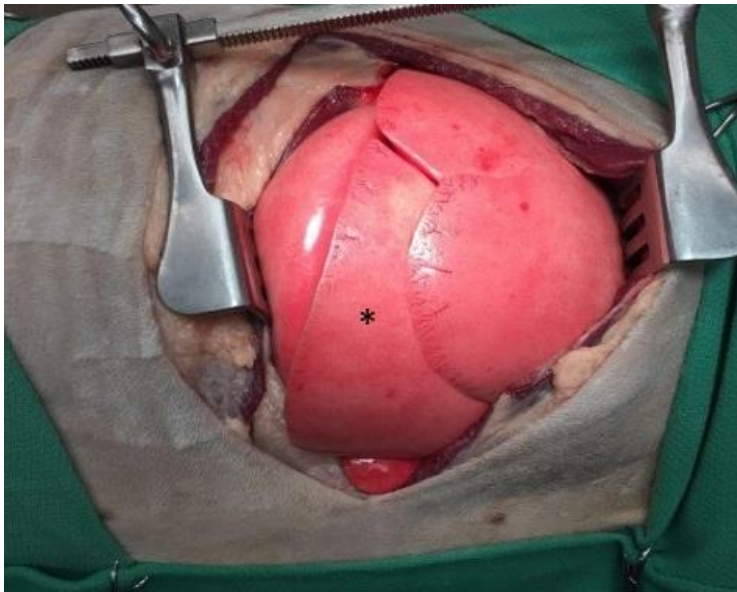

Figure 3. Right fifth intercostal thoracotomy with Finochietto rib retractor in place, for access to the right middle lung lobe (\*). Cranial is to the left, dorsal is at the top of the image.

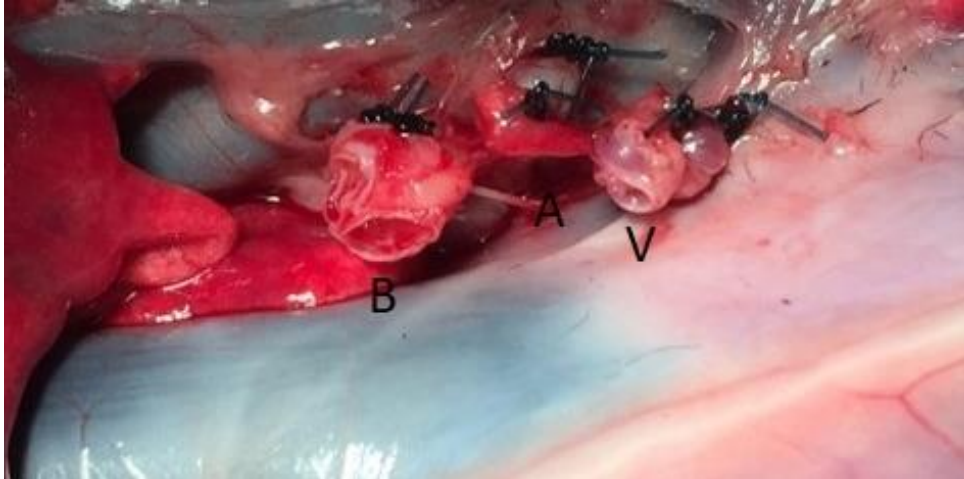

Figure 4. Suture ligation of bronchus (B), hilar artery (A), and vein (V), prior to oversewing bronchus. Cranial is to the left, dorsal is at the top of the image.



Figure 5. Articulating arm of the 2.0 mm Endo GIA™ stapler cartridge.

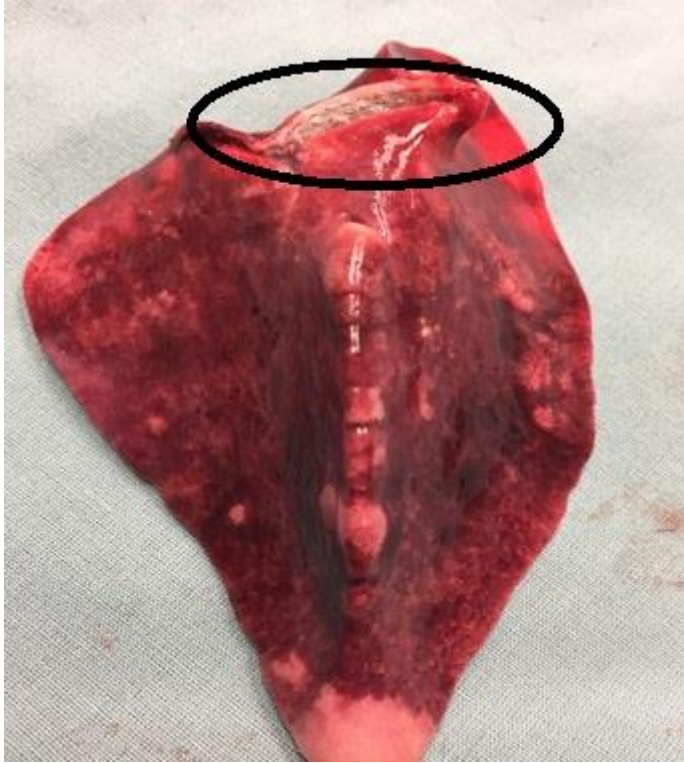

Figure 6. The three 2.0 mm staggered staple lines across hilum of the excised right middle lung lobe.

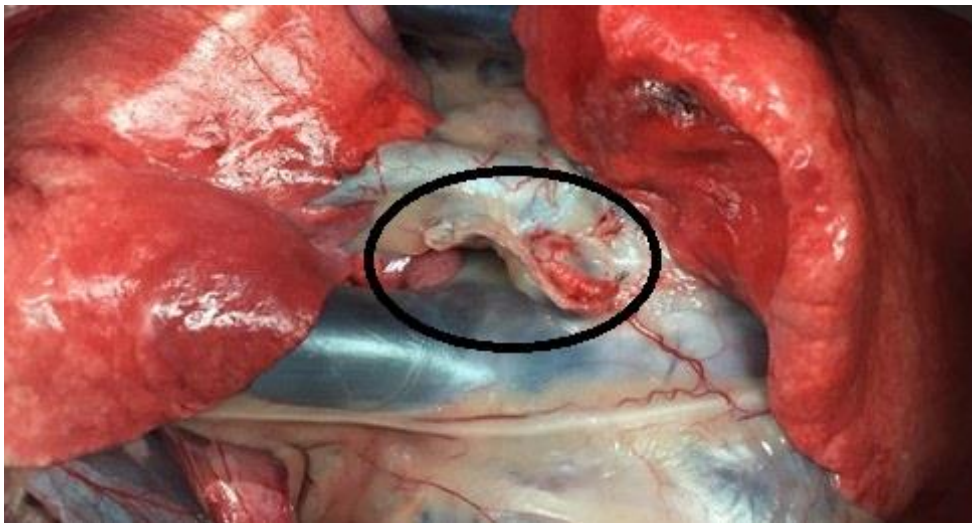


Figure 7. The three 2.0 mm staggered staple lines across hilum, intrathoracic view. Cranial is to the left, dorsal is at the top of the image.

### *2.3.3. Measures of Outcome*

Data collection included the procedure time, presence or absence of gas bubbles, and ability to maintain positive pressure at 20 cm H<sub>2</sub>O. Procedure time began after the thoracotomy was completed and the Finochietto rib retractor was placed, and as dissection around the hilum began for both groups. Time ended once the bronchus was oversewn in Group 1 (SL), and once the stapler was fired and released in Group 2 (ST), but before the thoracic cavity was filled with fluid. Presence or absence of air leakage was determined by the presence or absence of gas bubbles visualized when positive pressure was held at 20 cm H<sub>2</sub>O for 5 minutes as well as a drop or maintenance of positive pressure from 20 cm H<sub>2</sub>O.

### *2.3.4. Data Analysis*

The distribution of the data was evaluated using the Shapiro-Wilk test, skewness, kurtosis, and q-q plots. Body weight was normally distributed and was reported by the mean, standard deviation, and minimum-maximum values. Time for the procedure was not normally distributed. Attempts to log transform the data were not successful, thus the data are reported by the median, 25-75 percentiles, and minimum-maximum values. An independent samples t-test was used to determine if there was a significant difference in body weight by closure technique assignment. Levene's test was used to test for equality of variance. A Mann-Whitney test was used to determine if there was a significant difference in procedure time between closure techniques. Pearson's correlation test was used to determine if there was an association between procedure time and body weight. All analyses were conducted using commercially available

software (SPSS Statistics for Windows, version 24.0, IBM Statistics, Armonk, NY). A  $p < 0.05$  was used to determine statistical significance.

## 2.4. Results

The 2.0 mm Endo GIA™ stapler was used successfully in all cadavers assigned to Group 2 (ST). Body weight appeared to be evenly distributed, as there was no significant difference ( $t = -0.856$ ,  $p = 0.407$ ) in body weight between groups (SL, mean: 21.3, SD: 2.1, min-max: 19.3-25.4; ST, mean: 22.4, SD: 2.6, min-max: 18.6-25.4). The procedure times and air leakage are reported in Table 1. Procedure time was significantly shorter ( $p < 0.0001$ ) in lung lobectomies using the novel stapler (mean: 2.87, median: 2.70, SD: 0.96, 25-75%: 2.14-3.53, min-max: 1.55-4.57) compared to suture ligation (mean: 23.46, median: 21.75, SD: 8.22, 25-75%: 18.67-22.42, min-max: 17.65-43.3). There was no significant correlation ( $r = 0.044$ ,  $p = 0.873$ ) between body weight and procedure time. There were no incidents of air leakage or inability to maintain positive pressure at 20 cm H<sub>2</sub>O in either group.

Table 1. Demographics of study subjects and outcomes of surgical procedures

Case #	Body Weight (kg)	Group	Air Leakage Pressure at 20 cm H <sub>2</sub> O positive pressure	Procedure Time (min)
1	25.45	1 (SL)	None	43.3
2	20.27	1 (SL)	None	22.15
3	20.18	1 (SL)	None	22.2
4	23.82	1 (SL)	None	22.5
5	19.27	1 (SL)	None	21.35
6	25.36	2 (ST)	None	2.53

(table cont'd.)

<b>Case #</b>	<b>Body Weight (kg)</b>	<b>Group</b>	<b>Air Leakage Pressure at 20 cm H<sub>2</sub>O positive pressure</b>	<b>Procedure Time (min)</b>
7	23.55	2 (ST)	None	4.57
8	18.64	2 (ST)	None	2.05
9	24.18	2 (ST)	None	3.47
10	21.91	2 (ST)	None	3.55
11	21.18	1 (SL)	None	17.65
12	20.91	1 (SL)	None	18.03
13	19.73	1 (SL)	None	20.57
14	21.82	2 (ST)	None	2.88
15	18.73	2 (ST)	None	1.55
16	24.82	2 (ST)	None	2.42

SL, suture ligated; ST, stapled.



## CHAPTER 3. FINAL DISCUSSION AND CONCLUSIONS

### 3.1. Discussion

Total lung lobectomies were performed successfully in all cadavers between 18-27 kilograms using the novel 2.0 mm Endo GIA™ stapler. As such, our primary hypothesis was accepted. Procedure time was significantly shorter for stapled compared to suture ligated lung lobectomies. There were no incidents of air leakage in either group. Therefore, our secondary hypotheses were likewise accepted. There did not appear to be a size limitation within this study population of dogs between 18-27 kilograms, as all procedures were performed successfully.

Like in human medicine, a shift has occurred in veterinary medicine to favor minimally invasive procedures. In the human medical field, stapled lung lobectomies have been shown to be safe and effective.<sup>40,41,42</sup> More recent literature suggests that video- assisted thoracoscopic lung lobectomies in humans result in less wound pain and shorter hospital stays compared to open thoracotomy lung lobectomies.<sup>43-46</sup> Thus, increased surgical costs are offset by decreased hospitalization costs. To the authors' knowledge, there is only one prospective study comparing pain and morbidity in dogs undergoing open thoracotomies versus thoracoscopic procedures.<sup>47</sup> In this study, the dogs that underwent thoracoscopic pericardiectomies were less painful, had fewer wound complications, and returned to function more quickly. Considering that many surgeons and owners might prefer minimally-invasive procedures for these reasons, it is important to ensure that stapling devices utilized in thoracoscopic lung lobectomies are both effective and safe. The cohort of dogs in the current study (18-27 kg) was chosen to validate the use of this novel staple cartridge in a group of medium- to large-sized

dogs. There is also a need for investigation of stapling devices such as the 2.0 mm Endo GIA stapler for use in thoracic surgery in small-sized dogs as well as cats. Though staple sizes of 2.5 mm and 3.5 mm have been previously recommended,<sup>30,31,32</sup> to the author's knowledge, no studies have evaluated the ideal staple size for the veterinary population, specifically in dogs which range greatly in size. Smaller staples have theoretical advantages in small-sized canine and feline populations, allowing a more appropriate staple-to-tissue size match. This may allow more complete compression of the vessels and bronchus at the hilum and further limit air leakage and hemorrhage. Additionally, the articulating arm of this device is also advantageous in terms of maneuverability in the small working space in these patients. This benefit is not unique to total thoracoscopic surgery and is applicable to thoracoscopic-assisted and open procedures as well. Future studies are needed to investigate the use of this staple cartridge in small-sized dogs and cats.

One cadaver in Group 1 (case 1) had three pulmonary veins to dissect and ligate individually, prolonging the procedure time. When this outlier was excluded, the procedure time of lung lobectomies using the stapler remained significantly shorter than that of lung lobectomies using suture ligation ( $p < 0.0001$ ). This case demonstrates the variable anatomy of pulmonary vasculature, which can prolong procedure time with hand suturing but is of less consequence using a stapling device because all vessels are ligated and transected simultaneously. There did not appear to be a learning curve with the use of this stapler, as the procedure times were similar regardless of the number of lobectomies previously completed. Additionally, the stapler was subjectively easy to use, even for a novice surgeon.

This study has several limitations. All lung lobectomies were performed by a surgery resident in training. Relative inexperience may have led to artificial prolongation of the procedure time, particularly in the sutured lung lobectomies. There did not appear to be a learning curve, as the procedure times, with the exception of the outlier previously described, were similar among the remaining cadavers in the SL group. It is possible that there was an insufficient number of procedures to identify a learning curve.

No surgical assistant was utilized for the procedures in this study. In many cases with live patients, a sterile assistant is available for lung lobe retraction, cutting suture, and other steps of the procedures, increasing surgical efficiency and decreasing surgical time. It is possible that utilization of a surgical assistant would have decreased surgical time in these cadavers as well, though the difference in procedure time between groups likely would have remained statistically significant.

All lobectomies were performed on a single lung lobe (right middle lobe) in an attempt to standardize the approach and procedure. It is unlikely that the use of the stapler on other lobes would have changed the incidence of air leakage, though the procedure times likely would have been longer on lobes requiring transection of the pulmonary ligament. Additionally, all lobectomies were performed on lungs without gross disease. Large masses or abscesses can make exposure and exteriorization of the lung lobe more difficult, which may prolong surgical time.

Cadaveric work has inherent limitations. Cadaveric tissue, however fresh, may not exactly mimic the tissue of a live patient, especially in terms of its ability to form a seal at the lobectomy site. There is also absence of blood flow, which prevents evaluation of hemorrhage at the suture or staple line. In a live patient, the pulsatile

nature of blood vessels presents an additional stress to the lobectomy site. These pulses of blood exert pressure on the suture or staple line which may lead to hemorrhage that would not be identified in a cadaver.

The short-term design of the study also prevented assessment of slow air leakage and long-term thoracic contamination at the staple line. Therefore, it was not possible to identify patients in which incomplete closure of the tissue would have led to bacterial contamination or contamination with neoplastic cells in patients with infection and neoplasia, respectively.

There was no cost comparison performed between groups. The staple cartridge used in this study is substantially more expensive than suture. However, the shorter procedure time in a live patient would have decreased anesthesia and/or surgical costs, which can help offset the cost of the staple cartridge. In addition, especially when comparing the potential use of these cartridges in thoracoscopic procedures and assuming a similar trend as is seen in human medicine, decreased pain and hospitalization costs may also offset the increased instrument cost.

In conclusion, the 2.0 mm Endo GIA™ staple cartridge can be used successfully to perform total lung lobectomies in canine cadavers. Procedure time was significantly shorter for stapled lung lobectomies using the 2.0 mm Endo GIA™ staple cartridge compared to suture ligated lung lobectomies. Lastly, there were no incidents of air leakage in any of the procedures. The 2.0 mm Endo GIA™ stapler provides surgeons with an alternative, smaller cartridge size to use for lung lobectomies.

## CHAPTER 4. FUTURE DIRECTIONS

### 4.1. Future Directions

Future investigations to explore the use of the 2.0 mm Endo GIA™ stapler are manyfold. The bursting pressures of the bronchi sealed using this staple cartridge should be studied and compared with other staple cartridges and staplers. The positive pressure used in this study was maintained at physiologic airway pressure. However, normal patients may exceed 20 cm H<sub>2</sub>O temporarily with exercise or coughing, and suprathysiologic airway pressures were not tested. Additionally, the bursting pressure of the pulmonary arteries and veins should also be evaluated. This information would help determine the risk for postoperative hemorrhage, which was not assessed here. Using all this information, the 2.0 mm Endo GIA™ stapler could be directly compared to the currently recommended TA™ staple cartridges for lung lobectomy, including the 3.5 (blue) and 2.5 mm (white V3 vascular) cartridges. Histology could be used to evaluate the excised tissues for each device and assessed for complete closure of the vessels and bronchi. Because the ultimate goal is validation for use in live patients, the device should be evaluated in a live patient setting. It could be used for both open and thoracoscopic lung lobectomies, and the patients should be monitored for postoperative hemorrhage and air leakage. Once used in clinical patients, long term follow up could be performed to determine whether there is a difference in thoracic contamination from infection and/or neoplasia compared to other devices. These cartridges could also be evaluated for use in partial lung lobectomies.

Importantly, there is a lack of information on the size of the hilar vessels and bronchi in a range of canine patient size. As mentioned previously, current

recommendations for staple cartridge selection in lung lobectomies have not been made objectively. If the sizes of the vessels and bronchi have a significant range, which is likely given the large range in overall canine patient size, staple cartridge recommendations should be re-evaluated accordingly.

## APPENDIX. COPYRIGHT INFORMATION



**Alissa St. Blanc** <astblanc@gmail.com>  
to ogilvie ▾

Sep 21, 2021, 11:38 AM ☆ ↶ ⋮

Dr. **Ogilvie**,

I am completing my Master of Science degree at Louisiana State University, which includes the research published in this manuscript. I am writing to request written permission to use the published material within this manuscript in my Master's thesis. LSU asserts prior claim on theses and dissertations to the extent that LSU "reserves a nonexclusive, paid-up, royalty-free right to distribute copies of Course Materials, theses and dissertations, both internally and to third parties, whether by electronic means, microfilm, and otherwise." The thesis will be housed in the LSU Digital Commons open-access repository following its period of embargo. Please let me know if you have any questions or concerns.

Thank you,

Alissa St. Blanc  
Assistant Clinical Professor  
Companion Animal Surgery  
LSU School of Veterinary Medicine



**Kelly Gray** <kgray@cvma-acmv.org>  
to me ▾

Sep 21, 2021, 7:06 AM ☆ ↶ ⋮

Dear St. Blanc,

Thank you for your email and interest in seeking permission. Our permission policy allows for students to reuse published content from *The Canadian Veterinary Journal* for inclusion in doctoral dissertations at no cost.

I hereby give you permission to use "Investigation and Validation of a Novel Endo GIA Stapler for Canine Lung Lobectomies," published in *The Canadian Veterinary Journal*, (issue to be determined), please cite the appropriate attribution in your paper.

.Thank you,  
Kelly

**Kelly Gray-Sabourin**

Editorial Coordinator, Journals / Coordonnatrice de la rédaction, revues  
Canadian Veterinary Medical Association / Association canadienne des médecins vétérinaires  
339, rue Booth Street, Ottawa (Ontario) K1R 7K1  
t: 613-236-1162 x 117 / 800-567-2862  
f: 613-236-9681 e: [kgray@cvma-acmv.org](mailto:kgray@cvma-acmv.org)  
[www.canadianveterinarians.net](http://www.canadianveterinarians.net) [www.veterinairesauCanada.net](http://www.veterinairesauCanada.net)



**Timothy H Ogilvie** <ogilvie@upei.ca>  
to John, me, Kelly ▾

Sep 21, 2021, 7:22 AM ☆ ↶ ⋮

Hello Alissa.....yes, this is certainly permissible. I have copied Ms Kelly Gray Sabourin who can work with you on any paperwork that is required .....Best regards.....Tim  
**Ogilvie**

Dr. Timothy **Ogilvie**  
Co-Editor-in-Chief  
The Canadian Veterinary Journal



## REFERENCES

1. West JB. Mechanics of breathing. West JB. *Respiratory physiology: the essentials*. Ed 6. Lippincott Williams & Wilkins: Philadelphia; 2000:79–102.
2. Monnet E. Lungs. Johnston SA, Tobias KM. *Veterinary surgery: small animal*. ed 2. Elsevier: St Louis; 2018:1983-1999.
3. West JB. Gas transport by the blood. West JB. *Respiratory physiology: the essentials*. ed 6. Lippincott Williams & Wilkins: Philadelphia; 2000:63–102.
4. Ohnishi T, Ogura JH. Partitioning of pulmonary resistance in the dog. *Laryngoscope*. 1969;79:1847–1878.
5. Ohnishi T. Effects of nasal obstruction upon mechanics of the lung in the dog. *Laryngoscope*. 1971;81:712.
6. West JB. Control of ventilation. West JB. *Respiratory physiology: the essentials*. ed 6. Lippincott Williams & Wilkins: Philadelphia; 2000:103–115.
7. West JB. Diffusion. West JB. *Respiratory physiology: the essentials*. ed 6. Lippincott Williams & Wilkins: Philadelphia; 2000:21–28.
8. West JB. Ventilation-perfusion relationships. West JB. *Respiratory physiology: the essentials*. ed 6. Lippincott Williams & Wilkins: Philadelphia; 2000:45–62.
9. Cohn LA. Pulmonary parenchymal disease. Ettinger SJ, Feldman EC. *Textbook of veterinary internal medicine*. ed 7. Saunders/Elsevier: St Louis; 2010:1096-1119.
10. Creevy KE. Airway Evaluation and Flexible Endoscopic Procedures in Dogs and Cats: Laryngoscopy, Transtracheal Wash, Tracheobronchoscopy, and Bronchoalveolar Lavage. *Vet Clin N Am Small Anim Pract*. 2009;39:869-880.
11. Schmeidt C. Small Animal Exploratory Thoracoscopy. *Vet Clin N Am Small Anim Pract*. 2009;39:953-964.
12. DeBerry JD, Norris CR, Samii VF, et al. Correlation between fine-needle aspiration cytopathology and histopathology of the lung in dogs and cats. *J Am Anim Hosp Assoc*. 2002;38:327.
13. Ettinger SJ. Diseases of the trachea and upper airways. Ettinger SJ, Feldman EC. *Textbook of veterinary internal medicine*. ed 7. Saunders/Elsevier: St Louis; 2010:1066-1088.



14. Oppenheimer N, Klainbart S, Merbl Y, et al. Retrospective evaluation of the use of autologous blood-patch treatment for persistent pneumothorax in 8 dogs (2009–2012). *J Vet Emerg Crit Care*, 2014;24:215-220.
15. Murphy KA, Brisson BA. Evaluation of lung lobe torsion in Pugs: 7 cases (1991-2004). *J Am Vet Med Assoc*. 2006;228:86-90.
16. Neath PJ, Brockman DJ, King LG. Lung lobe torsion in dogs: 22 cases (1981-1999). *J Am Vet Med Assoc*. 2000;217:1041-1044.
17. Teske E, Stokhof AA, van der Ingh TS, et al. Transthoracic needle aspiration biopsy of the lung in dogs with pulmonic disease. *J Am Anim Hosp Assoc*. 1991;27:289–294.
18. O'Brien MG, Straw RC, Withrow SJ, et al. Resection of pulmonary metastases in canine osteosarcoma: 36 cases (1983-1992). *Vet Surg*. 1993;22:105-109.
19. Culp WT, Olea-Popelka F, Sefton J. et al. Evaluation and prognostic factors for dogs living greater than one year after diagnosis of osteosarcoma: 90 cases (1997-2008). *J Am Vet Med Assoc*. 2014;245:1141-1146.
20. Turner H, Seguin B, Worley DR, et al. Prognosis for dogs with stage III osteosarcoma following treatment with amputation and chemotherapy with and without metastasectomy. *J Am Vet Med Assoc*. 2017;251:1293-1305.
21. Davis KM, Roe SC, Mathews KG, Mente PL. Median sternotomy closure in dogs: a mechanical comparison of technique stability. *Vet Surg*. 2006;35:271-277.
22. Pelsue DH, Monnet E, Gaynor JS, Powers BE, Halling K, Parker D, Golden A. Closure of median sternotomy in dogs: suture versus wire. *J Am Anim Hosp Assoc*. 2002;38:569-576.
23. Lansdowne JL, Monnet E, Twedt DC, Dernell WS. Thoracoscopic lung lobectomy for treatment of lung tumors in dogs. *Vet Surg*. 2005;34:530–535.
24. Mayhew PD, Hunt GB, Steffey MA, et al. Evaluation of short-term outcome after lung lobectomy for resection of primary lung tumors via video-assisted thoracoscopic surgery or open thoracotomy in medium- to large-breed dogs. *J Am Vet Med Assoc*. 2013;243:681–688.
25. Wormser C, Singhal S, Holt DE, Runge JJ. Thoracoscopic-assisted pulmonary surgery for partial and complete lung lobectomy in dogs and cats: 11 cases (2008-2013). *J Am Vet Med Assoc*. 2014;245:1036-1041.
26. Majeski SA, Steffey MA, Mayhew PD, et al. Postoperative Respiratory Function and Survival After Pneumonectomy in Dogs and Cats. *Vet Surg*. 2016;45:775-781.

27. Lucas CL. Effects of pneumonectomy on pulmonary input impedance. *Surgery*. 1983;94:807.
28. Lores ME. Cardiovascular effects of positive end-expiratory pressure (PEEP) after pneumonectomy in dogs. *Ann Thorac Surg*. 1985;40:464.
29. Anagnostou TL, Pavlidou K, Savvas I, et al. Anesthesia and perioperative management of a pneumonectomized dog. *J Am Anim Hosp Assoc*. 2012;48:145–149.
30. Walshaw R. Stapling techniques in pulmonary surgery. *Vet Clin N Am Small Anim Pract*. 1994;24:334-366.
31. LaRue SM, Withrow SJ, Wykes PM. Lung resection using surgical staples in dogs and cats. *Vet Surg*. 1987;16:238–240.
32. Tobias KM. Surgical stapling devices in veterinary medicine: a review. *Vet Surg*. 2007;36:341-349.
33. Veterinary Medical Products. Medtronic Animal Health [Brochure]. c 2021 [updated April 2021]. Available from: <https://www.medtronic.com/content/dam/covidien/library/us/en/product/veterinary-medical-supplies/animal-health-product-catalog-brochure.pdf> Last access March 10, 2022.
34. Hess JL. Use of mechanical staples in veterinary thoracic surgery. *J Am Anim Hosp Assoc*. 1979;15:569.
35. Bleakley S, Duncan CG, Monnet E. Thoracoscopic Lung Lobectomy for Primary Lung Tumors in 13 Dogs. *Vet Surg*. 2015;44:1029-1035.
36. Mayhew PD, Culp WT, Pascoe PJ and Arzi NV. Use of the Ligasure Vessel-Sealing Device for Thoracoscopic Peripheral Lung Biopsy in Healthy Dogs. *Vet Surg*, 2012;41:523-528.
37. Marvel S and Monnet E. *Ex Vivo* Evaluation of Canine Lung Biopsy Techniques. *Vet Surg*, 2013;42:473-477.
38. Brückner M, Heblinski N, and Henrich M. Use of a novel vessel-sealing device for peripheral lung biopsy and lung lobectomy in a cadaveric model. *J Small Anim Pract*, 2019;60:411-416.
39. Cronin, AM, Pustelnik, SB, Owen, L, Hall, JL. Evaluation of a pre-tied ligature loop for canine total lung lobectomy. *Vet Surg*. 2019;48:570– 577.
40. Lewis RJ. Simultaneously stapled lobectomy: A safe technique for video-assisted thoracic surgery. *J Thorac Cardiovasc Surg*. 1995;109:619-625.

41. Lewis RJ, Caccavale RJ, Sisler GE, Bocage JP, Mackenzie JW. One hundred video-assisted thoracic surgical simultaneously stapled lobectomies without rib spreading. *Ann Thorac Surg.* 1997;63:1415-1422.
42. Lewis RJ, Caccavale RJ. Video-assisted thoracic surgical non-rib spreading simultaneously stapled lobectomy (VATS(n)SSL). *Sem Thorac Cardiovasc Surg.* 1998;10:332-339.
43. Mafé JJ, Planelles B, Asensio S, et al. Cost and effectiveness of lung lobectomy by video-assisted thoracic surgery for lung cancer. *J Thorac Dis.* 2017;9:2534–2543.
44. Swanson SJ, Meyers BF, Gunnarsson CL, et al. Video-assisted thoracoscopic lobectomy is less costly and morbid than open lobectomy: a retrospective multiinstitutional database analysis. *Ann Thorac Surg.* 2012;93:1027-1032.
45. Menna C, Ibrahim M, Rendina EA, Venuta F, Andreetti C. Cost/efficacy evaluation of the technologies applied to video-assisted thoracoscopic surgery lobectomy. *J Vis Surg.* 2017;3:152.
46. Lacin T, Swanson S. Current costs of video-assisted thoracic surgery (VATS) lobectomy. *J Thorac Dis.* 2013;5:S190–S193.
47. Walsh PJ, Remedios AM, Ferguson JF, Walker DD, Cantwell S, Duke T. Thoracoscopic versus open partial pericardectomy in dogs: comparison of postoperative pain and morbidity. *Vet Surg.* 1999;28:472– 479.

## VITA

Alissa Walsh St. Blanc, born in Ruston, Louisiana, is the daughter of Mrs. Christine Marie McIntosh and Mr. Patrick Michael Walsh. She is the older sister of Adam Taylor Walsh. Alissa attended Louisiana State University in Baton Rouge, Louisiana, and majored in Animal, Dairy, and Poultry Sciences. During this time, she met her husband, Michael Paul St. Blanc. Alissa was accepted into the LSU School of Veterinary Medicine (LSU SVM) and graduated with her Bachelor of Science degree following completion of her first year of veterinary school in 2013. Throughout her years at LSU SVM, her passion for small animal surgery became evident. She graduated from LSU SVM in 2016 and then completed a one year rotating small animal medicine and surgery internship at Texas A&M University College of Veterinary Medicine. She then underwent further training during a small animal surgery internship at the Dallas Veterinary Surgery Center. She was offered a small animal surgery residency at LSU SVM in 2018 and elected to pursue a concurrent Master of Science degree. She and her husband welcomed their son, Paul Francis St. Blanc, in 2019, and their daughter, Nora Claire St. Blanc, in 2022. Alissa has completed her residency, achieved board certification, and currently holds the position of Assistant Professor of Companion Animal Surgery at LSU SVM. She plans to receive her Master of Science degree in May 2022. In her free time, she enjoys spending time in the outdoors and with her family, two cats, and two dogs.